

# Cancer of Unknown Primary Origin

EVANGELOS BRIASOULIS, NICHOLAS PAVLIDIS

Department of Medicine/Oncology Unit, Ioannina University Hospital, Ioannina, Greece

*Key Words.* Unknown primary. Unknown origin. Occult cancer. Carcinoma. Metastasis. Incidence. Diagnosis. Treatment

## ABSTRACT

About 3% of all cancer patients suffer from cancer of unknown primary origin. These patients present with metastatic disease for which a primary site cannot be detected at the time of diagnosis. Sophisticated diagnostic techniques and operational procedures have failed to improve the diagnostic efficacy in this group of patients. Consequently, a limited diagnostic procedure with basic laboratory tests and imaging studies is sufficient for the diagnosis of this syndrome. The use of immunohistochemistry, as well as serum tumor

markets of high specificity that may help to identify other tumors, is highly suggested. Although the prognosis for the majority of these patients still remains poor, several subsets of favorable outcome to treatment have been recognized. Nevertheless, promising in vitro data and new drugs on trials, paralleled with a better knowledge of the underlying pathogenetic molecular mechanisms, offer a more optimistic look to the future therapeutic management of these patients. *The Oncologist* 1997; 2: 142 - 152.

## INTRODUCTION

Cancer of unknown primary origin (CUP) represents a group of heterogeneous tumors that share a unique clinical feature: "early" apparent metastatic disease with no identifiable site of origin at the time of presentation. Thus CUP patients present with usually widespread metastatic disease for which no primary site can be detected after a good medical history, detailed clinical examination, and extensive investigations. The primary site may either have a slow growth or may possibly become involute and therefore unlikely to manifest itself.

In spite of notable progress in imaging technology and immunohistochemistry and the introduction of serum tumor markers in the everyday clinical practice, CUP still imposes a diagnostic and therapeutic dilemma to the practicing oncologist - that is, how far to take the investigational procedures and how aggressively to treat these patients who constitute a group of approximately 3% of all cancer patients.

## DEFINITION

The definition as well as the nomenclature itself of cancer of unknown primary site or origin have been varied over time and from one series to another under the influence of inclusion criteria and the evolution of diagnostic tools used.

The common term for this group of diseases is "carcinoma of unknown primary" which underscores the fact that the patients with metastatic disease in the absence of a discernible primary site. Historically, the simplest clinical definition has included all patients who presented with histologically confirmed metastatic carcinoma and in whom a complete medical history, careful physical examination, and chest radiography did not identify the primary site (1). How-

ever, today a basic blood and biochemistry survey, stool occult blood testing, urinalysis, histopathologic review of biopsy material with the use of immunohistochemistry, and computed tomography of abdomen and pelvis are needed to define this group of patients (2).

## HISTOLOGIC CLASSIFICATION

According to routine light microscopy, cancers of unknown primary origin are divided into four major subtypes (3):

\*Adenocarcinomas well to moderately differentiated

\* Poorly differentiated carcinoma and adenocarcinoma.

\* Squamous cell carcinomas.

\* Undifferentiated neoplasms.

The majority of cases are adenocarcinomas, with poorly differenti-

Table 1. Proportions of reported histologic diagnoses in CUP

Author	Number of CUP patients	Adenocarcinoma (%)	Undifferentiated to poorly differentiated carcinoma (%)	Squamous cell carcinoma (%)	Other* (%)
Muir (7)	25,060	47.7	22.0	19.5	8.8
Holmes (30)	686	28.0	16.0	10.0	46.0
Abruzzese (10)	657	58.2	29.4	5.8	6.7
Le Chevalier (14)	302	45.0	22.5	15.0	12.5
Buda (81)	332	65.0	14.0	21.0	

\*Includes undifferentiated neoplasms, other specified and unknown histotypes.

ated tumors being the next most frequent pathology (Table 1). Squamous cell carcinoma is a special minor subtype involving mainly the cervical nodes, and undifferentiated neoplasms are frequently reclassified to major histologic categories (i.e., carcinoma, lymphoma, melanoma, sarcoma) because of the improvements of the histopathology techniques.

Metastatic melanoma with an unknown primary and CCUP in children are usually discussed separately; metastatic melanoma with an unknown primary has the same propensities, biology, and survival as metastatic cutaneous melanoma (4,5). In childhood, embryonal malignancies make up the majority of the rare cases of disseminated malignancies without an identified primary site (6). Clinical characteristics of the major CUP histologic types are depicted in Table 2.

## CLINICAL FEATURES

### Epidemiology - Demographics

CUP comprises approximately 3% of human

cancer. The average annual age - adjusted incidence is 7 - 12 cases per 100,000 population per year (7), and as a cause of death it is reported to be the fourth most common among cancer - related deaths in developed countries (8,9). Demographics of CUP patients generally mirror those of the general cancer population, with a mean of 59 at diagnosis (range 20 - 89) (10) and a marginally higher frequency in males. Squamous cell carcinomas are twice as frequent in males in females, while there is a compensatory shift in the frequency of adenocarcinomas (7). In children, CUP represents <1% of diagnosed solid tumors (6).

It is remarkable that, regardless of the probable differences in the investigational strategies in several countries, no substantial difference in the prevalence of these tumors among cancer patients has been recorded worldwide (Table 3). The large variation of CUP prevalence reported in several studies actually represents referrals to hospital - based oncology units and depends on referral patterns, patient selection, and center specification (11, 12).

**Natural History**

Early dissemination, clinical absence of primary tumor, unpredictable metastatic pattern, and aggressiveness constitute the fundamental characteristics of these tumors (Table 4). Understandably, apart from this general approach, a precise natural history of this heterogeneous cluster of neoplasms cannot easily be established. Early dissemination is reflected in the clinical absence of symptoms related to a primary tumor and even more in the relative failure of autopsy to localize the site of tumor origin. Several studies report that autopsy has failed to identify the primary site in 15% - 25% of CUP cases (13, 14). Between the identified occult primaries, lung and pancreas constitute the majority, while other common malignancies represent smaller proportions (1, 2, 14 - 19) (Fig. 1). CUP has a tendency toward a

**Table 2. Clinical characteristics of the major CUP histologic types**

	Mean age (range)	Major sites involved	Specific clinical characteristics	Main treatment effectiveness	5-Year relative survival rates (%)
Adenocarcinoma (well to moderately differentiated) (3)	58	Liver, lung, bone	The most frequent type in adults; poor prognosis	Chemotherapy Palliative	4
		Axillary lymph nodes only (subtype) (30, 82)	Females; relatively good prognosis	Locoregional Effective	60
		Peritoneum only (subtype) (35, 83)	Females; relatively good prognosis; response to chemotherapy and survival similar to ovarian cancer	Platinum-based chemotherapy Effective	12
Poorly differentiated carcinomas (84)	37 (17-70)	Lymph nodes of midline distribution, lung	Rapid tumor growth, favorable response to chemotherapy	Platinous-based chemotherapy Effective (57% ORR)*	13-16
Squamous cell carcinoma (54, 55, 85)	60	Cervical lymph nodes	Male:female ratio of 6:1	Locoregional or platinum-based chemotherapy Effective	50
Embryonal malignancies (6)	8 (1-17)	Bone marrow, bone lesions, lymph nodes, lung	Predominating type in childhood	Carboplatin-doxorubicin- ifosfamide-based chemotherapy regimens Effective	17

ORR= overall response rate

**Table 3. Frequencies of CUP among diagnosed malignancies**

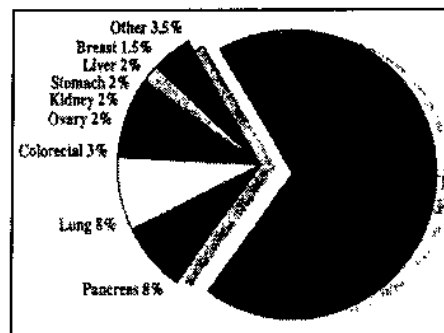
Country	Frequency (%)	Remarks
USA (7)	2.3	SEER* program, period 1973-1987. Frequency of microscopically confirmed CUP cases among more than one million histologically diagnosed cancer cases. A light decline in the number of cases was observed during this period.
Australia (9)	4.2	Period 1970-1990. Weak point: absence of histologically proven diagnoses is reported for patients over 75 years old in this study (New South Wales Registry).
Finland (86)	2.5	
Germany (8)	7.8	Registration of cases of death by cancer of the whole population of the Federal Republic of Germany during period 1968-1984. Weak points: A) Cancer death registration gives a false higher incidence for this group of tumors; B) histologic verification 80%; C) loose diagnosis for old patients.
Russia (87)	3.6	Dnepropetrovsk region. Weak point: registry of a relatively small population area.

\*Surveillance, Epidemiology and End Results

commonly to develop bone metastases (17). Obviously, this unpredictability complicates the search for a primary site. Apart from having the propensity for early dissemination, these tumors

**Table 4. CUP: Predisposing characteristics**

- ▲ Early dissemination
- ▲ Clinical absence of primary at presentation
- ▲ Unpredictable metastatic pattern
- ▲ Aggressiveness



**Figure 1. Distribution of identified primary tumor sites reported among 2,114 cases with CUP [1,2,14-19].**

can be characterized as particularly aggressive ones. The very short elapsed time between first symptoms and diagnosis is an indication of the speed of tumor increase (21).

The clinical presentation in cases of CUP depends on the predominant site of metastatic involvement. Regarding the organ sites affected most patients (60%) have more than two sites affected at presentation (2), with lymph nodes being the most frequently involved. Liver, lung, bone, and pleura con-

metastatic pattern different from that expected for the primary neoplasm if eventually found. For example, while bone metastases are usual in breast or prostate cancer, as a manifestation of CUP they are usually attributed to lung, liver, or renal occult primary (20). Similarly, occult prostate cancer manifests with liver and lung secondaries, while the usual natural history of this cancer is most

stitute common metastatic sites, whereas relatively high frequencies of odd localizations of metastases have been observed (14, 22, 23). General deterioration and weight loss are the most common symptoms, while digestive and respiratory symptoms, liver enlargement, ascites, skin nodules, and bone pains suggest the sites of predominant metastatic involvement.

### Prognosis

The overall prognosis in patients with CUP is poor, with a mean survival of five to ten months (10, 11). Fewer than 25% of patients survive up to one year, but survival differs among clinicohistological subgroups (Table 2). Significant prognostic factors recognized in CUP are: histopathology, organs involved, tumor burden, gender and performance status (Table 5). The prognostic significance of histological type can be attributed to the chemosensitivity of the underlying occult primary in each category. In poorly differentiated carcinomas, several tumors chemosensitive in origin may be included, whereas adenocarcinomas usually represent chemotherapy-resistant primaries.

Lymph node metastatic topography deserves separate mention, since several distinct subgroups of prognostic significance have been recognized. Cervical nodes with squamous cell cancer, axillary nodes with adenocarcinomas in females, and lymph nodes with undifferentiated carcinomas constitute presentations of a favorable prognosis. Supraclavicular lymph node involvement has been defined as a bad prognostic factor.

### DIAGNOSIS

#### Pursuing the Anatomical Location, or Searching for Clues to Treatable Tumors?

The search for the identification of the occult primary has always challenged clinicians. The argument in favor of pursuing the anatomical location of the primary is the belief that localizing the primary might result in a more specific and effective treatment. In a minority of CUP patients, a primary site of origin can indeed be identified after extensive diagnostic evaluation, but exhaustive investigations have been criticized because of a low yield and a lack of influence on patients prognosis (14). Such a strategy has never been found to have any therapeutic implications or to be of survival benefit to the patient. On the contrary, it costs the patient a longer hospital stay, with the experience of painful and distressing investigations and the health care system an unac-

ceptable cost-effectiveness ratio (24). Although the phenomenon of performing all available sophisticated tests on these patients in the everyday clinical practice is not uncommon, practicing oncologists have always been skeptical about performing speculative low-yield investigations (15). Moreover, a limited diagnostic approach with patient-benefit orientations has now been justifiably proposed (2).

Regarding the identification of treatable subgroups, a careful consideration of the clinical presentation of the disease with an optimal re-evaluation of the biopsy specimen provides the best clue. Immunohistochemistry and, in exceptional cases, molecular genetic and cytogenetic studies may help the diagnosis (25, 26). This way, the well-recognized clinicopathological subsets of treatable and potentially curable tumors can easily be identified, and any histological misclassifications can be clarified (27). Such a strategy that can lead to optional management of treatable tumors underlines the necessity for the collaboration and interaction between clinician and pathologist.

### Proposed Diagnostic Strategy

As a rule a reasonable diagnostic approach to CUP patients is to avoid excessive diagnostic procedures without compromising clinically useful diagnostic efficacy.

Based on the initial clinical presentation and pathology report, the diagnostic strategy for a probable CUP should be divided into the standard and optional diag-

Table 5: Prognostic factors in CUP [10, 11, 29]

	Favorable factors	Negative factors
Pathology	<ul style="list-style-type: none"> <li>Poorly differentiated carcinoma</li> <li>Squamous cell carcinoma</li> <li>Neuroendocrine carcinoma</li> </ul>	<ul style="list-style-type: none"> <li>Adenocarcinoma</li> </ul>
Organs involved	<ul style="list-style-type: none"> <li>Lymph nodes (except supraclavicular)</li> </ul>	<ul style="list-style-type: none"> <li>Liver, lung, bones</li> <li>≥ three sites</li> </ul>
Tumor burden		<ul style="list-style-type: none"> <li>Male</li> </ul>
Gender	<ul style="list-style-type: none"> <li>Female</li> </ul>	<ul style="list-style-type: none"> <li>≥4</li> </ul>
Performance status*	<ul style="list-style-type: none"> <li>0-1</li> </ul>	<ul style="list-style-type: none"> <li>≥1.25 N</li> </ul>
Alkaline phosphatase *	<ul style="list-style-type: none"> <li>≤1.25 N</li> </ul>	

\* Analyzed in undifferentiated carcinomas.

Standard Diagnostic Investigations [2]

Pathology	Histopathologic review of the biopsy material with the use of immunohistochemistry
Laboratory tests	Full blood count, routine biochemistry, fecal occult blood testing, urine test
Imaging studies	Chest radiography, CT scan of abdomen and pelvis
Optional or symptom/signs-oriented investigations	
Imaging studies	CT scan of head and neck region in cervical node cases Mammography for axillary lymph node metastases
Endoscopies	ENT panendoscopy, bronchoscopy, proctoscopy, colonoscopy
Surgeries	Mastectomy in axillary cases, cytoreductive laparotomy for peritoneal carcinomatosis

nostic procedures (Table 6).

The standard diagnostic procedure for the majority of these patients is proposed to include the histopathologic review of biopsy material with the use of immunohistochemistry, full blood count, routine biochemistry, fecal occult blood testing, urine testing, chest radiography, and computed tomography of abdomen and pelvis. It must be emphasized that immunohistochemistry staining for common leukocyte antigen, CEA, cytokeratin and vimentin is considered today a routine pathology procedure for these tumors. For the subgroups of the cervical node epidermoid carcinomas and the axillary adenocarcinomas in females, more specific initial investigational procedures are advisable; those include ENT panendoscopy and head and neck CT scanning in cases of cervical lymph nodes, and mammography in axillary lymph node metastases in women. Other recommended optional investigations are the high specificity alpha-fetoprotein (AFP), beta-human chorionic gonadotropin (b-HCG), and prostate-specific antigen (PSA) serum tumor markers in men to exclude ex-

tragonadal germ cell tumor or prostate, cancer, and symptoms - or signs - oriented endoscopies. Surgical diagnostic procedures have not gained a wide acceptance.

### Evaluation of Diagnostic Methods

#### Physical Examination

The physical examination must always be a thorough one and should include head and neck, thyroid, and rectal examination. In women, breast and pelvis, and in men, prostate and testicles examination should never be overlooked,

#### Imaging Studies

Although chest radiography has always been a prerequisite for the diagnosis of CUP, its usefulness in the differential diagnosis between primary and secondary disease in lungs has been disputed [17].

Computed tomography is considered today one of the most valuable imaging tests in CUP cases. It has a clearly proven impact on CUP diagnosis, offering an additional diagnostic accuracy of 20% in cases previously characterized as CUP [28]. CT scan also helps the evaluation of tumor mass and provides guidance to biopsy procedure.

Most barium studies have failed to contribute to the detection of the primary [17] and to the overall management and survival improvement [15], so should only rarely if ever be used. Mammography has been proposed as a basic test in women with metastatic adenocarcinomas in axillary lymph nodes [29], but its sensitivity in this context was found to be low [30].

#### Endoscopy

Endoscopies should always be symptoms - or signs-oriented investigational procedures in CUP cases.

ENT panendoscopy with fine-needle aspiration has been proposed as the initial diagnostic approach in cases of cervical node involvement [31]. Fiber optic bronchoscopy is advisable in cases of radiographic indications or symptoms, given the high frequency of the lung as the occult primary and the failure of radiography to differentiate primary and secondary tumor in the CUP setting [17]. Proctoscopy and colposcopy seem to be of practical interest in cases of inguinal lymph node involvement [32].

#### Surgery

Surgery as a diagnostic procedure has a definite role in biopsy sampling [33]. In cases of women with adenocarcinomas of the peritoneum, cytoreductive laparotomy has a therapeutic rather than a diagnostic benefit [34,35].

#### Pathology

Histopathology is the cornerstone in the diagnostic procedure of CUP. A good biopsy specimen is of great importance, especially in cases of poorly differentiated tumors, and for the application of special pathology techniques that can improve the diagnosis of chemosensitive tumors which are sub-

ject to misdiagnosis. By definition, conventional light microscopy cannot identify the site of origin [36] or define any prognostic characteristics of responsiveness to chemosensitivity [37]. Identifying the primary site is not an easy task for conventional histopathology, especially in metastatic adenocarcinoma cases. Interestingly, a correct diagnosis of only 48% was achieved by pathologists when they were shown 100 metastatic adenocarcinomas of known primary origin which were presented as unknowns with the provision of minimal essential clinical data. A higher accuracy was achieved for prostate, ovarian, and breast carcinomas, and a lower accuracy for the upper gastrointestinal tract, biliary tract, and pancreatic adenocarcinoma [38].

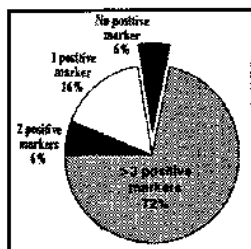
Immunohistochemistry is the most useful diagnostic tool and the central axis of the initial basic investigation, especially in cases of poorly differentiated carcinomas [36, 39]. Immunoperoxidase staining has now become widely available and can be reliably applied on routinely fixed paraffinembedded biopsy materials. It uses specific monoclonal or polyclonal antibodies directed against a wide range of antigens: specific membrane antigens, cytoskeleton proteins, secreted proteins, enzymes, hormonal receptors, and other cell elements. Immunocytochemistry can also be applied on cytological preparations in cases of malignant perusions [40]. Today, with the help of a wide range of immunohistochemistry markers, the misdiagnosis of other malignancies such as lymphomas, extragonadal germ cell tumors, malignant melanomas, and undifferentiated sarcomas as CUP is rather rare. Nevertheless, it should always be kept in mind that regardless of the relatively high specificity of several immunoperoxidase markers, false positive as well as false negative staining may be expected. Differences in fixation techniques and in the kind of antigen used are responsible for the observed differences in sensitivity and specificity [36].

The clinical importance of immunoperoxidase staining in the differential diagnosis of poorly differentiated CUP has recently been evaluated. At the Vanderbilt Center, a series of biopsy samples of 87 cases diagnosed before the immunohistochemistry period (1978-1983) were re-evaluated with the use of immunoperoxidase staining techniques. Different diagnoses resulted in 16% of the cases: eight malignant melanomas, four lymphomas, one prostate cancer, and one yolk sack tumor [41].

#### Advanced Diagnostic Tests

Electron microscopy can be a useful diagnostic tool in 15% of undifferentiated CUP not otherwise identified by light microscopy, offering an additional accuracy in one-third of these cases [42-44]. It is a well-reputed diagnostic method for the poorly differentiated neuroendocrine tumors and amelanotic melanomas recognizing core granules, electron - dense secretory granules, and premelanosomes. It can also contribute to the diagnosis of dedifferentiated squamous cell tumors (desmosomes attached to tonofilaments), adenocarcinomas (acinar spaces, tight junctions, and microacini) and sarcomas (myofibrils, dilated rough endoplasmic reticulum, extra-

**Figure 2. Multiple overexpression of 6 serum tumor markers (CEA, CA 19-9, CA 15-3, CA 125, HCG, AFP) evaluated in 58 CUP cases.**



cellular osteoid). Disadvantages of electron microscopy are the special handling procedure, the experienced personnel, and the expensive equipment required.

Molecular genetic and cytogenetic studies can offer today additional diagnostic information toward the identification of special tumor types that have specific genetic markers [45-47]. Fluorescence in situ hybridization (FISH) using the chromosomal marker *i(12p)* [48], which is highly nonrandom for germ cell tumors, has been proven an excellent diagnostic tool in atypical extragonadal germ cell tumors presenting as undifferentiated CUP [25]. Genetic analysis can also contribute to the diagnosis of a number of tumors with specific chromosomal aberrations, usually seen in soft tissue sarcomas and lymphomas [49]. Nasopharyngeal undifferentiated carcinomas can be distinguished from dedifferentiated epidermoid tumors by detection of EBV genome with PCR analysis [50].

#### Serum Tumor Markers

Males should always have the high-specificity tumor markers b-HCG, AFP, and PSA tested to exclude treatable extragonadal germ cell tumors and prostate cancer amenable to endocrine treatment. In children, testing for urinary catecholamines can produce valuable diagnostic clues, as high urine levels are diagnostic of neuroblastoma. In all other cases, routine evaluation of current, commonly used serum tumor markers have not been proven of any prognostic or diagnostic assistance, and a non-specific multiple overexpression in the majority of CUP patients has been observed [51] (Fig. 2).

#### Treatment

A reasonable treatment approach for CUP patients is to individualize the treatment, taking into consideration the most appropriate modality for each case, whether locoregional, systemic, curative, palliative, or supportive.

#### Locoregional Treatment

Being by definition a metastatic disease, CUP leaves only limited room for locoregional treatment practises, radiotherapy, and surgery. Locoregional treatment of curative orientation should be considered in cases of isolated axillary node metastases in females [52, 53] and squamous cell metastases in cervical nodes, especially in  $<N_2$  stages [54, 55]. For higher stages ( $N_3$ ), combination modality treatment with radiochemotherapy is proposed as a more reasonable approach, offering a better response rate and survival [56]. Palliative locoregional treatment should be offered in cases of local complications such as spinal cord compression, bowel obstruction, pathological bone fraction, etc.

#### Systemic Treatment

Although curative in few cases of CUP, chemotherapy constitutes the mainstream of treatment practises for the majority of patients with this systemic metastatic disease.

#### Potentially Curable CUP Subgroups

Notable advances have been made over the past decade in the treatment of poorly differentiated CUP. Although it has been proposed by some investigators that these tumors should be challenged as a whole with cisplatin-based combination regimens with the intent of achieving long-lasting responses in a number of patients [57], several subgroups of CUP have been identified as potentially curable.

The better-defined, potentially curable subpopulation is young adults, primarily males, with poorly differentiated carcinomas having as dominant tumor sites the mediastinum, retroperitoneum, lungs, or peripheral lymph nodes. In these patients, a 16% actuarial 10-year survival has been achieved [58, 59]. It has recently been shown by molecular and cytogenetic studies that response to cisplatin therapy in those patients correlated with the finding of *i(12p)* in tumor, a specific chromosomal marker characterizing germ cell tumors [25].

Another well-documented subset of patients with favorable response to platinum-based chemotherapy and improved prognosis is women with peritoneal carcinomatosis [34, 35]. Patients with advanced lymph node metastases from an epidermoid carcinoma have also been shown to achieve long-term survival when treated with platinum-based combination chemotherapy [60]. Cure is also possible for the rare cases of children with CUP if treated with chemotherapy regimens effective against embryonal malignancies [6].

An indicative synopsis of effective treatment approaches in patients with CUP is presented in Table 2.

#### Adenocarcinoma: Supportive, Palliative or Investigational Treatment Approach?

Unfortunately, the favorable subsets of CUP constitute a minority. The large majority of adenocarcinomas of unknown primary origin (ACUP) still remain resistant to clinically established chemotherapy. The regimens used so far have been empirical and of palliative orientation [61], and the observed responses in most retrospective studies were moderate, with no definite impact on survival [58]. Four randomized trials and more than a dozen non-randomized ones with combinations of several chemotherapy agents published during the last 20 years yielded on average a crude response rate of 25% [62]. The conclusion of almost all of these studies was pessimistic [63-67] - poor responses and no significant impact on survival. Our experience with a carboplatin - based combination regimen in a phase II trial gave comparable results with other regimens and no long-term disease-free survivors. Because of the lack of any effective treatment, therapeutic trials are much needed in this category of patients to improve the hope of cure and the ability to palliate.

ACUP patients should either be treated in an investigational setting with agents holding clinical promises, or they should be given low-toxicity treatment of palliative orientation or even supportive care only. Quality of life is a major point in these cases and should be taken very seriously into consideration because of the poor performance status and prognosis of these patients.

#### Future Treatment Perspectives

Some interesting *in vitro* data have been published recently regarding chemosensitivity of ACUP [68]. Two hundred seventy-eight agents were tested in 313 freshly explanted tumor specimens of ACUP in a tumor-cloning system. The higher response rates (>20%) were observed for paclitaxel, actinomycin - D, methotrexate, vinblastine, and melphalan, while most of the compounds clinically characterized inactive in ACUP were shown less active *in vitro* as well. Interestingly enough, and in support of the *in vitro* finding of paclitaxel chemosensitivity, we have observed that CUP highly overexpress the p53 protein [69], and there is now evidence of activity of taxoids in tumors with aberrant p53 function [70, 71]. These new data may be seen as a potential therapeutic promise, and further clinical development of these agents in the ACUP setting is warranted.

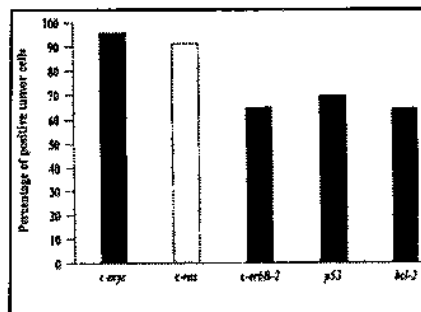
#### Search for Genetic Identity - Biological Profile

Regardless of being a relatively common clinical entity and in spite of its obvious biological significance, CUP has attracted only limited research attention to date. The reason is probably the relatively short life of a well-recognized clinical entity with a grim prognosis.

The search for genetic damage has taken a central role in cancer research in the last decade [72]. In clinical practise, it already offers a useful diagnostic and prognostic tool, while at the same time opening wide horizons to a deeper understanding of carcinogenesis, identification of malignant diseases, and search of new treatment targets. Regarding CUP, such studies are very limited. They aim not only to identify special tumor types but also mostly to recognize a common identity in these tumors, if any. Consistent structural anomalies involving chromosome 1 have been observed in a small number of CUP cases including deletions, duplication, and the presence of a homogeneous staining region [73, 74]. Abnormalities in chromosome 1 have generally been reported in several malignant diseases [47, 75], but

most importantly they have been associated with advanced malignancy [76]. It has been supported that some oncosuppressor gene may be located in the short that some chromosome 1 whose aberration might lead to the expression of a metastatic phenotype [77].

**Figure 3. Immunohistochemical detection of oncoproteins in CUP [69, 79]. (c-myc, c-erbB-2 and ras were studied in 26 cases, p53 and bcl-2 in 47 CUP cases).**



It has been proposed that CUP progresses to malignancy via a unique (type II) series of molecular and accelerated biochemical events, and that the cellular interactions with the host are different from malignancies where the primary is known [78]. A unique biological profile is also suggested by our observations that show an extremely high overexpression of several tumor markers [51] and oncoproteins in these tumors [69, 79] (Fig. 3). Nevertheless, no pattern of expression of these biological markers was found, and neither prognostic nor diagnostic significance was proven. The research for the genetic identity and the biological profile of these tumors remains an open challenge to the investigators.

#### Conclusions

The heterogeneous-in-origin tumors that present clinically as CUP share common clinical features of early metastatic dissemination from an occult primary. A limited diagnostic evaluation toward the detection of the primary tumor and a thorough clinicopathological evaluation for clues to identify the well-recognized, treatable subgroups are recommended. As a significant therapeutic improvement has not been achieved for the majority of patients with metastatic adenocarcinomas, innovative treatment approaches with the introduction of new classes of drugs into trials are warranted. Findings suggestive of a unique biological profile of CUP have recently been evidenced and justify further research for the genetic and biologic identity of these aggressive tumors that express an absolute metastatic phenotype.

#### REFERENCES

1. Stewart JF, Tattersall MH, Woods RL et al. Unknown primary adenocarcinoma: incidence of overinvestigation and natural history. *Br Med J* 1979;1:1530 - 1533
2. Abbruzzese JI, Abbruzzese MC, Lenzi R et al. Analysis of a diagnostic strategy for patients with suspected tumours of unknown origin. *J Clin Oncol* 1995;13:2094 - 2103
3. Greco FA, Hainsworth JD. Cancer of unknown primary site. In: DeVita TV, Hellman S., Rosenberg SA, eds. *Cancer: Principles and Practice of Oncology*. 4th ed. Philadelphia: J.B. Lippincott Co., 1993: 2072 - 2092.
4. Norman J, Cruse CW, Wells KE et al. Metastatic melanoma with an unknown primary. *Ann Plast Surg* 1992; 28: 81 - 84.
5. Akslen LA, Hartveit F. Metastatic melanoma of unknown origin at autopsy. *Eur J Surg Oncol* 1988;14:379 - 382.
6. Kutesch JF, Parham DM, Kaste SC et al. Embryonal malignancies of unknown primary origin in children. *Cancer* 1995; 75:115 - 21.
7. Muir C. Cancer of unknown primary site. *Cancer* 1995;75:353 - 356.
8. Neumann G. The impact of cancer with unspeci-

- fied site. *Off Gesundheitswes* 1988; 50:13 - 19.
9. Coates M, McCredie M, Taylor R. NSW Central Cancer Registry and Cancer Epidemiology Research Unit, eds. *Cancer in New South Wales. Incidence and Mortality 1990*. Sidney: NSW Cancer Council, 1992.
  10. Abbruzzese JL, Abbruzzese MC, Hess KR et al. Unknown primary carcinoma: natural history and prognostic factors in 657 consecutive patients. *J Clin Oncol* 1994; 12:1272 - 1280.
  11. Altman E, Cadman E. An analysis of 1539 patients with cancer of unknown primary site. *Cancer* 1986; 57:120 - 124.
  12. Didolkar MS, Fanous N, Elias EG et al. Metastatic carcinomas from occult primary tumours. *Ann Surg* 1997; 186:625 - 630.
  13. Mayordomo JL, Guerra JM, Guijarro C et al. Neoplasms of unknown primary site: a clinicopathological study of autopsied patients. *Tumori* 1993; 79:321 - 324.
  14. Le Chevalier T, Cvitkovic E, Caille P. et al. Early metastatic cancer of unknown primary origin at presentation: a clinical study of 302 consecutive autopsied patients. *Arch Intern Med* 1988; 148:2035 - 2039.
  15. Hamilton CS, Langlands AO. ACUPS (adenocarcinoma of unknown primary site): a clinical and cost benefit analysis. *Int J Radiat Oncol Biol Phys* 1987; 13:1497 - 1503.
  16. Kirsten F, Cli CH, Leary JA et al. Metastatic adeno or undifferentiated carcinoma from an unknown primary site - natural history and guidelines for identification of treatable subsets. *Q J Med* 1987; 62:143 - 161.
  17. Nystrom JS, Weiner JM, Wolf Meshnik R. et al. Identifying the primary site in metastatic cancer of unknown origin. Inadequacy of roentgenographic procedures. *JAMA* 1979; 241:381 - 383.
  18. Moertel CG, Reitemeier RJ, Schutt AJ et al. Treatment of the patient with adenocarcinoma of unknown origin. *Cancer* 1972; 30:1469 - 1472.
  19. Osteen RT, Kopf G, Wilson RE. In pursuit of the unknown primary. *Am J Surg* 1978; 135:494 - 498.
  20. Shih LY, Chen TH, Lo WH. Skeletal metastasis from occult carcinoma. *J Surg Oncol* 1992; 51:109 - 113.
  21. Leonard RJ, Nystrom JS. Diagnostic evaluation of patients with carcinoma of unknown primary tumor site. *Semin Oncol* 1993; 20: 244 - 250.
  22. Ringeberg QS, Doll DC, Yarbrow JW et al. Tumors of unknown origin in the bone marrow. *Arch Intern Med* 1986; 146:2027 - 2028.
  23. Bigner SH, Johnston WW. The diagnostic challenge of tumors manifested initially by the shedding of cells in cerebrospinal fluid. *Acta Cytol* 1984; 28:29 - 36.
  24. Levine MN, Drummond MF, Labelle RJ. Cost - effectiveness in the diagnostic and treatment of carcinoma of unknown primary origin. *Can Med Assoc J* 1985; 133:977 - 987.
  25. Motzer RJ, Rodriguez E, Reuter VE et al. Molecular and cytogenetic studies in the diagnosis of patients with poorly differentiated carcinomas of unknown primary site. *J Clin Oncol* 1995; 13:274 - 282.
  26. Van der Gaast A, Verweij J, Planting AST et al. The value of immunohistochemistry in patients with poorly differentiated adenocarcinomas and undifferentiated carcinomas of unknown primary. *J Cancer Res Clin Oncol* 1996; 122:181 - 185.
  27. Guthrie TH. Treatable carcinoma of unknown origin. *Am J Med Sci* 1989; 298:74 - 78.
  28. Karsell RP, Sheedy FP II, O'Connell JM. Computed tomography in search of cancer of unknown origin. *JAMA* 1982; 248:340 - 343.
  29. Dodion P, De Valeriola D. Diagnosis and treatment of unknown primary tumors. *Bull Cancer Paris* 1989; 76:939 - 946.
  30. Baron PL, Moore MP, Kinne DW et al. Occult breast cancer presenting with axillary metastases. Updated management. *Arch Surg* 1990; 125:210 - 214.
  31. Lefebvre JL, Coche Dequeant B, Van JT et al. Cervical lymph nodes from an unknown primary tumor in 190 patients. *Am J Surg* 1990; 160: 443-446.
  32. Mousseau M, Schaerer R, Lutz JM et al. Hepatic metastasis of unknown primary site. *Bull Cancer Paris* 1991; 78: 725-736.
  33. Tytor M, Olofsson J. Cervical lymph node metastases with occult primary, *Clin Otolaryngol* 1986; 11: 463-437.
  34. Strnad CM, Grosh WW, Baxter JW et al. Peritoneal carcinomatosis (pc) of unknown primary site in women: results of treatment for presumed ovarian cancer (oc) (meeting abstract). *Proc Ann Meet Am Soc Clin Oncol* 1986; 5: 18.
  35. Muggia FM, Baranda J. Management of peritoneal carcinomatosis of unknown primary tumor site. *Semin Oncol* 1993; 20: 268-272.
  36. Mackay B, Ordonez NG. Pathological evaluation of neoplasms with unknown primary tumor site. *Semin Oncol* 1993; 20: 206-228.
  37. Hainsworth JD, Wright EP, Gray GF et al. Poorly differentiated carcinoma of unknown primary site: correlation of light microscopic findings with response to cisplatin-based combination chemotherapy. *J Clin Oncol* 1987; 5: 1275-1280.
  38. Sheahan K, O'Keane JC, Abramowitz A et al. Metastatic adenocarcinoma of an unknown primary site: a comparison of the relative contributions of morphology, minimal essential clinical data and cea immunostaining status. *Am J Clin Pathol* 1993; 99: 729-735.
  39. Matthews P, Ellis IO. Use of immunocytochemistry in the diagnosis of metastatic carcinoma. *Ann Med* 1996; 28: 297-300.
  40. Mottolise M, Ventura I, Donnorso RP et al. Use of selected combinations of monoclonal antibodies to tumor associated antigens in the diagnosis of neoplastic effusions of unknown origin. *Eur J Cancer Clin Oncol* 1988; 24: 1277-1284.
  41. Hainsworth JD, Wright EP, Johnson DH et al. Poorly differentiated carcinoma of unknown primary site: clinical usefulness of immunoperoxidase staining. *J Clin Oncol* 1991; 9: 1931-1938.
  42. Hammar S, Bockus D, Remington F. Metastatic tumors unknown origin: an ultrastructural analysis of 265 cases. *Ultrastruct Pathol* 1987; 11: 209-250.
  43. Horn T, Andersen CB, Nerstrom H. Election microscopy of needle biopsies from cancer patients with unknown tumours. *Ugeskr Laeger* 1995; 155: 1126-1129.



44. Hainsworth JD, Johnson DH, Greco FA. Poorly differentiated neuroendocrine carcinoma of unknown primary site. A newly recognized clinicopathologic entity. *Ann Intern Med* 1988; 109: 364-371.
45. Turc-Carel C, Philip I, Berger MP et al. Chromosomal translocation in Ewing's sarcoma. *N Engl J Med* 1983; 309: 497-498.
46. Atkin NB, Baker MC. Specific chromosome change, i(12p), in testicular tumors. *Lancet* 1982; 1349-1356.
47. Mathew S, Murty VV, Bosl GJ et al. Loss of heterozygosity identifies multiple sites of allelic deletions on chromosome 1 in human male germ cell tumors. *Cancer Res* 1994; 54: 6265-6269.
48. Bosl GJ, Ilson DH, Rodriguez E et al. Clinical relevance of the i(12p) marker chromosome in germ cell tumors. *J Nat Cancer Inst* 1994; 86: 349-355.
49. Ilson DH, Motzer RJ, Rodriguez E et al. Genetic analysis in the diagnosis of neoplasms of unknown primary tumor site. *Semin Oncol* 1993; 20: 229-237.
50. Feinmesser R, Miyazaki I, Cheung R et al. Diagnosis of nasopharyngeal carcinoma by DNA amplification of tissue obtained by fine needle aspiration. *N Engl J Med* 1992; 326: 17-21.
51. Pavlidis N, Kalef Ezra J, Briassoulis E et al. Evaluation of six tumor markers in patients with carcinoma of unknown primary. *Med Pediatr Oncol* 1994; 22: 162-167.
52. Ellerbroek N, Holmes F, Singletary E et al. Treatment of patients with isolated axillary nodal metastases from an occult primary carcinoma consistent with breast origin. *Cancer* 1990; 66: 1461-1467.
53. Whillis D, Brown PW, Rodger A. Adenocarcinoma from an unknown primary presenting in women with an axillary mass. *Clin Oncol R Coll Radiol* 1990; 2: 189-192.
54. Nguyen C, Shenouda G, Black MJ et al. Metastatic squamous cell carcinoma to cervical lymph nodes from unknown primary mucosal sites. *Head Neck* 1994; 16:58-63.
55. Bataini JP, Jaulerry C, Rodriguez J et al. Management of metastatic squamous cell carcinoma in cervical nodes from an occult primary tumor (meeting abstract). *Am J Clin Oncol* 1985;8:24
56. Jeremic B, Djuric LJ, Jevremovic S et al. Metastatic squamous cell carcinoma of an unknown primary tumor localized to the neck. *J Chemother* 1992;4:41-45
57. van der Gaast A, Verweij J, Henzen Logmans SC et al. Carcinoma of unknown primary: identification of a treatable subset? *Ann Oncol* 1990;1:119-122.
58. Hainsworth JD, Greco FA. Treatment of patients with cancer of an unknown primary site. *N Engl J Med* 1993;329:257-263.
59. Greco FA, Vaughn WK, Hainsworth JD. Advanced poorly differentiated carcinoma of unknown primary site: recognition of a treatable syndrome. *Ann Intern Med* 1986;104:547-553.
60. Pavlidis N, Kosmidis P, Skarlos D et al. Subsets of tumors responsive to cisplatin or carboplatin combinations in patients with carcinoma of unknown primary site. *Ann Oncol* 1992;3:631-634.
61. Sporn JR, Greenberg BR. Empirical chemotherapy for adenocarcinoma of unknown primary tumor site. *Semin Oncol* 1993;20:261-267.
62. Lindeman GJ, Tattersall MH. Tumours of unknown primary site. In: Peckham M, Pinedo HM, Veronesi U, eds. *Oxford Textbook of Oncology*. Oxford: Oxford University Press, 1996.
63. Walach N, Horn Y. Combination chemotherapy in the treatment of adenocarcinoma of unknown primary origin. *Cancer Treat Rep* 1987;71:605-607
64. van der Gaast A, Verweij J, Planting AS et al. 5-fluorouracil, doxorubicin and mitomycin c (fam) combination chemotherapy for metastatic adenocarcinoma of unknown primary. *Eur J Cancer Clin Oncol* 1988;24:765-768.
65. Bedikian AY, Bodey GP, Valdivieso M et al. Sequential chemotherapy for adenocarcinoma of unknown primary. *Am J Clin Oncol* 1983;6:219-224.
66. Eagan RT, Therneau TM, Rubin J et al. Lack of value for cisplatin added to mitomycin-doxorubicin chemotherapy for carcinoma of unknown primary site. A randomized trial. *Am J Clin Oncol* 1987;10:82-85.
67. Milliken ST, Tattersall MH, Woods RL et al. Metastatic adenocarcinoma of unknown primary site. A randomized study of two combination chemotherapy regimens. *Eur J Cancer Clin Oncol* 1987;23:1645-1648.
68. Hanauske AR, Clark GM, Von Hoff DD. Adenocarcinoma of unknown primary: retrospective analysis of chemosensitivity of 313 freshly explanted tumors in a tumor cloning system. *Invest New Drugs* 1995;13:43-49.
69. Briassoulis E, Tsokos M, Fountzilas G et al. p53 and bcl-2 protein expression in metastatic carcinomas of unknown primary (CUP). *Ann Oncol* 1996;7:(suppl 5)5.
70. Wahl AF, Donaldson KL, Fairchild C et al. Loss of normal p53 function confers sensitization to Taxol by increasing G<sub>2</sub>/M arrest and apoptosis. *Nat Med* 1996;2:72-79.
71. Vasey PA, Jones NA, Jenkins S et al. Cisplatin, camptothecin, and taxol sensitivities of cells with p53-associated multidrug resistance. *Mol Pharmacol* 1996;50:1536-1540.
72. Bishop JM. The molecular genetics of cancer. *Science* 1987;235:305-311.
73. Abbruzzese JL, Lenzi R, Raber MN et al. The biology of unknown primary tumors. *Semin Oncol* 1993;20:238-243.
74. Bell CW, Pathak S, Frost P. Unknown primary tumors: establishment of cell lines, identification of chromosomal abnormalities, and implications for a second type of tumor progression. *Cancer Res* 1989;49:4311-4315.
75. Fong CT, Dracopoli NC, White PS et al. Loss of heterozygosity for the short arm of chromosome 1 in human neuroblastomas: correlation with n-myc amplification. *Proc Natl Acad Sci USA* 1989;86:3753-3757.
76. Olah E, Balogh E, Kovacs I et al. Abnormalities of chromosome 1 in relation to human malignant diseases. *Cancer Genet Cytogenet* 1989;43:179-194.
77. Solomon E, Borrow J, Goddard AD. Chromosome aberration and cancer. *Science* 1991;254:1153-1160.
78. Frost P. Unknown primary tumors: an example of accelerated (type 2) tumor progression (19 refs). *Ba-*



sic Life Sci 1991;57:233-237.

79. Pavlidis N, Briassoulis E, Bai M et al. Overexpression of C-myc, Ras and C-erbB-2 oncoproteins in carcinoma of unknown primary origin. *Anticancer Res* 1995;15:2563-2568.

80. Holmes F, Fouts T. Metastatic cancer of unknown primary site. *Cancer* 1970;26:816-820.

81. Buda F, De Gregori L, Salamanca S et al. Neoplasms with unknown primary location. *Recenti Prog Med* 1990;81:486-492.

82. Haupt HM, Rosen PP, Kinne DW. Breast carcinoma presenting with axillary lymph node metastases. An analysis of specific histopathologic features. *Am J Surg Pathol* 1985;9:165-175.

83. Strnad C, Gosh WW, Baxter JW. Peritoneal carcinomatosis of unknown primary site in women. *Ann Intern Med* 1989;111:213-217.

84. Hainsworth JD, Dial TW, Greco FA. Curative combination chemotherapy for patients with advanced poorly differentiated carcinoma of unknown primary site. *Am J Clin Oncol* 1988;11:138-145.

85. Coster JR, Foote RL, Olsen KD et al. Cervical nodal metastasis of squamous cell carcinoma of unknown origin: indications for withholding radiation therapy. *Int J Radiat Oncol Biol Phys* 1992;23:743-749.

86. Parkin DM, Muir CS, Whelan SL et al. Cancer incidence in five continents. Vol. VI. IARC Scientific Publication No.120. Lyon.1992.

87. Komov DV, Komarov IG, Podregul'skii KR et al. Cancer metastases from an unestablished primary tumour (clinical aspects, diagnosis, treatment). *Sov Med Rev F Oncology* 1991;4:1-33.

88. Pasterz R, Savaraj N, Burgess M et al. Analysis of prognostic factors in patients with metastatic carcinoma of unknown primary (mcup)(meeting abstract). *Proc Ann Meet Am Soc Clin Oncol* 1985;4:151.

89. van der Gaast A, Verweij J, Planting AST et al. Simple prognostic model to predict survival in patients with undifferentiated carcinoma of unknown primary site. *J Clin Oncol* 1995;13:1720-1725.